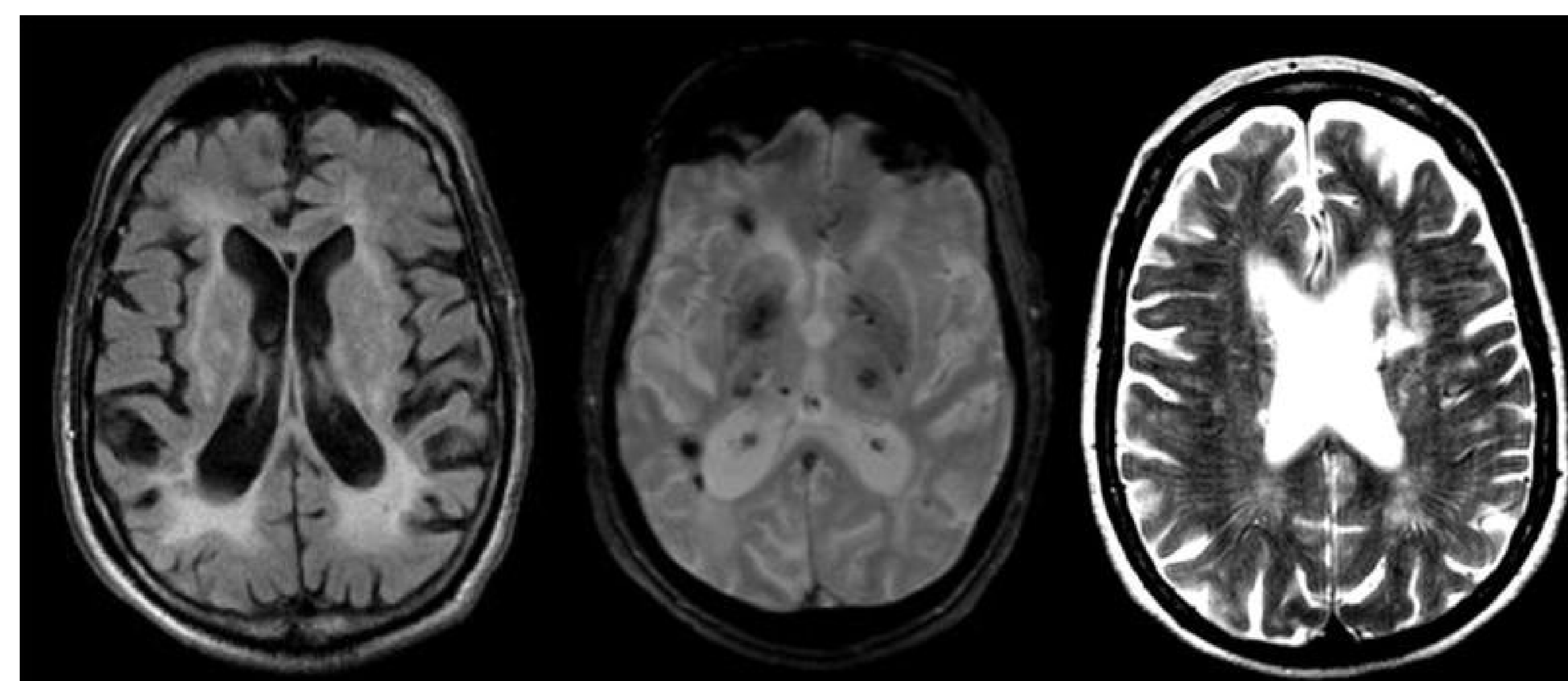


## Rehabilitation approach in managing Binswanger's disease with cervical dystonia: Case Report

Dr. Zainab Al Lawati, MD, MEd, FRCPC, FAAPMR  
Department of Rehabilitation  
University of Minnesota

### CASE DESCRIPTION

A 67 year old female presented to our clinic for progressive memory issues, gait instability and neck rotation to the right associated with tremor. Physical examination noted for normal strength with symmetric hyper-reflexia. Patient's cognitive evaluation noted some perseveration. After a comprehensive evaluation by neurology and after excluding orthopedic causes, Binswanger's disease was diagnosed.



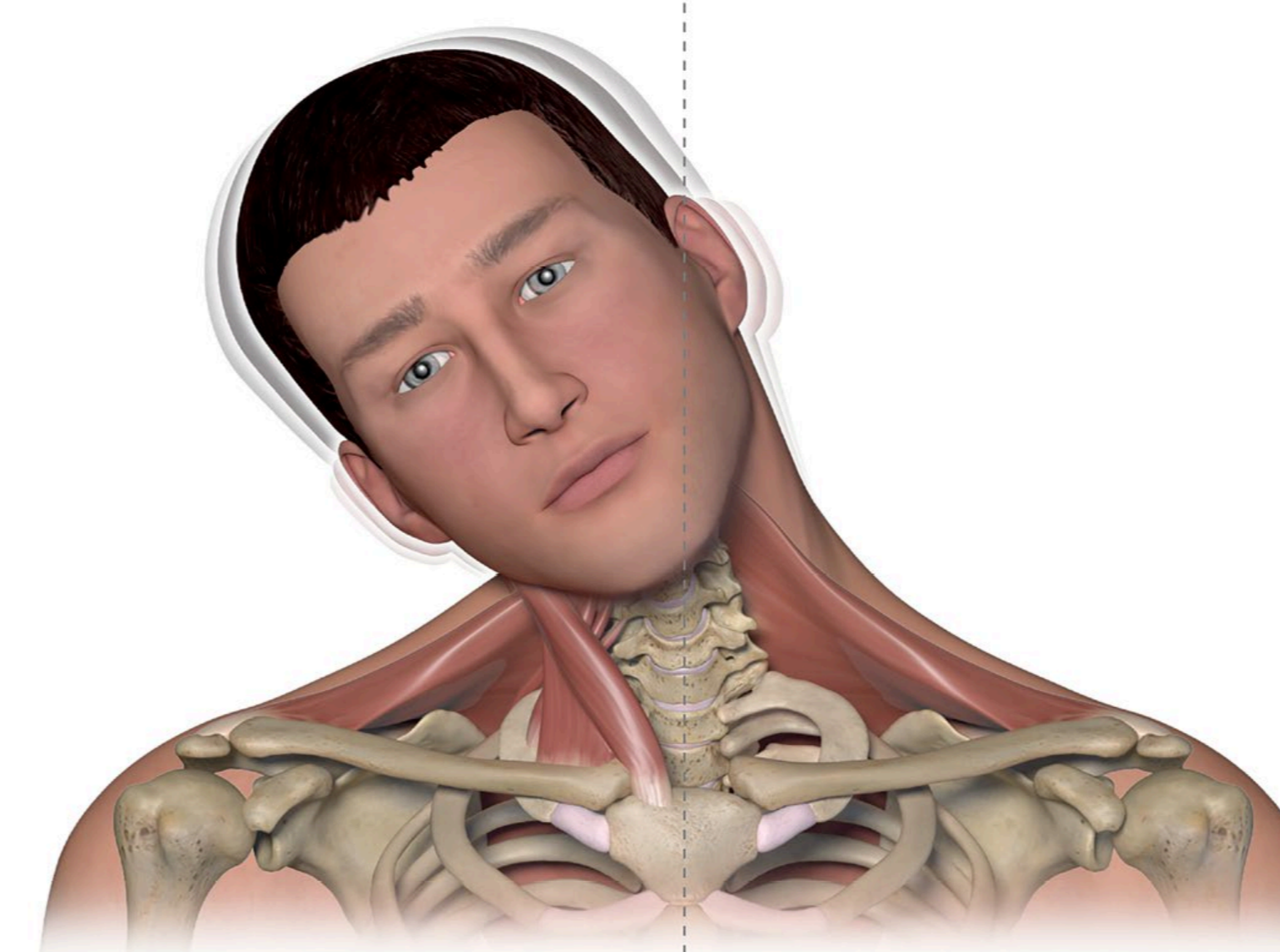
Imaging features of Binswanger's disease.

- Large white matter hyperintensities with white matter atrophy in FLAIR.
- Subcortical microhemorrhages (black dots) on Echo gradient.
- Dilated perivascular spaces on T2.

### REHABILITATION COURSE

Patient's cardiovascular risk factors were optimized. Functional evaluation was completed by physical and occupational therapies and patient was referred to physical medicine and rehabilitation for cervical dystonia management. Patient tried multiple oral anti-spasticity medications such as Baclofen and Tizanidine but did not result in dystonia management.

A trial of chemodenervation using botulinum toxin to the right Scalene complex, Sternocleidomastoid and upper Trapezius resulted in better control over cervical dystonia and resolution of neck tremors. Patient reported better control over neck muscles and better quality of life.



Combination posture: Right laterocollis, tremor

### DISCUSSION

Binswanger's disease is a progressive form of cerebral small vessel disease affecting the white matter and other subcortical structures. Patients with Binswanger's disease often have different degrees of cognitive impairment. They also develop upper motor neuron signs including tremor, spasticity and dystonia.

On physical examination there are usually asymmetric hyperreflexia and mild parkinsonism. Managing patients with Binswanger's disease requires a multidisciplinary approach and symptomatic management. Dystonia alongside with spasticity may require medication management including Baclofen and Gabapentin. Chemodenervation using botulinum toxin can help improve cervical dystonia. If all conservative measures fail, deep brain stimulation can be considered to control dystonia that interferes with quality of life.

### CONCLUSION

Binswanger disease is a progressive neurological disorder affecting the blood vessels that supply the white-matter. Clinical presentation can involve upper motor neuron signs such as cervical dystonia. The literature is scarce regarding the prognosis of the disease and there is currently no cure available. Optimizing cardiovascular risk factors is the key in managing this disease.